

# Size Matters: Ab Interno Canaloplasty Revision with Suture Trabeculotomy

Roland Seif<sup>1</sup>, Nahia Dib El Jalbout<sup>2</sup>, Ama Sadaka<sup>3</sup>, Andrei-Alexandru Szigiato<sup>4</sup>, Paul Harasymowycz<sup>5</sup>

Received on: 18 May 2022; Accepted on: 28 September 2022; Published on: 23 January 2023

## ABSTRACT

**Aim:** To report the efficacy of the revision of failed ab interno canaloplasty with micro-invasive suture trabeculotomy (MIST) over a follow-up period of 24 months.

**Materials and methods:** A retrospective analysis was performed on 23 eyes with open-angle glaucoma (OAG), on whom an ab interno canaloplasty revision with MIST was performed for glaucoma progression. The primary outcome was the proportion of eyes with a significant intraocular pressure (IOP) reduction at 12 months post trabeculotomy, defined as an IOP  $\leq$  18 mm Hg or  $\geq$ 20% reduction in IOP without any secondary intervention (SI), and with the same or fewer number of glaucoma medications (NGM). All parameters, including best corrected visual acuity (BCVA), IOP, NGM, and SI, were evaluated at 1, 6, 12, 18, and 24 months.

**Results:** At 12 months, eight out of 23 eyes (36.4%) achieved complete success, maintained in six eyes (27.3%) at 24 months. A significantly lower mean IOP was recorded at all visits [ $14.3 \pm 4.0$  mm Hg at 24 months vs  $23.1 \pm 6.8$  mm Hg at baseline (BL)] with a percent IOP change of up to 27.3% at 24 months postoperatively. NGM and BCVA did not significantly decrease from BL. A total of 11 eyes (47.8%) needed an SI throughout the follow-up period.

**Conclusion:** Ab interno trabeculotomy in patients with failed canaloplasty was not shown to be effective in providing a satisfactory control of IOP in OAG patients, possibly due to the small suture gauge used in the initial canaloplasty.

**Clinical significance:** Further research is needed to optimize the surgical outcome.

**Keywords:** Canaloplasty, Micro-invasive suture trabeculotomy, Minimally invasive glaucoma surgery, Retrospective analysis.

*Journal of Current Glaucoma Practice* (2022): 10.5005/jp-journals-10078-1387

## INTRODUCTION

Glaucoma is the leading cause of irreversible blindness and the second most common cause of irreversible moderate to severe vision impairment worldwide in those aged 50 years or older, with 3.6 million cases and 4.13 million cases reported in 2020, respectively.<sup>1</sup> Although its pathophysiology has not been fully elucidated; disease progression is known to be halted or delayed by lowering the IOP.<sup>2</sup> IOP is regulated by aqueous humor production by the ciliary body and aqueous humor outflow primarily in the region of Schlemm's canal. The trabecular meshwork (TM) and the inner wall of Schlemm's canal are the areas of greatest resistance to aqueous outflow and, thus, are the target of ab externo trabeculectomy. Filtration surgery for the treatment of advanced glaucoma is considered as the gold standard for decades.<sup>3</sup> It has shown high efficacy in the treatment of glaucoma, and unlike tube filtration surgery, it allows the titration of the IOP-lowering effect after surgery. However, it is limited by the potentially devastating short-term and long-term postoperative complications of traditional incisional glaucoma filtration surgery, including hypotony with secondary maculopathy or choroidal effusion, hyphema, bleb leak, blebitis, and endophthalmitis.<sup>3,4</sup> Therefore, alternative surgical procedures, referred to as minimally invasive glaucoma surgeries (MIGS), have been developed to help lowering IOP in glaucoma patients and reduce their need for medical treatment while minimizing the risks of traditional glaucoma filtration surgeries. MIGS include bleb-forming surgeries or nonbleb-forming surgeries that either decrease the inflow or improve the trabecular or uveoscleral outflow of aqueous humor.<sup>4</sup>

<sup>1-3</sup>Department of Ophthalmology, Lebanese American University (LAU) Medical Center-Rizk Hospital, Beirut, Lebanon

<sup>4,5</sup>Department of Ophthalmology, Université de Montréal, Montreal, Quebec, Canada

**Corresponding Author:** Nahia Dib El Jalbout, Department of Ophthalmology, Lebanese American University (LAU) Medical Center- Rizk Hospital, Beirut, Lebanon, Phone: +96101200800, e-mail: jalbout.nahia@gmail.com

**How to cite this article:** Seif R, Jalbout NDE, Sadaka A, et al. Size Matters: Ab Interno Canaloplasty Revision with Suture Trabeculotomy. *J Curr Glaucoma Pract* 2022;16(3):152–157.

**Source of support:** Nil

**Conflict of interest:** None

Canaloplasty is a bleb-independent ab interno Schlemm's canal filtration surgery, it lowers the IOP through viscodilation of Schlemm's canal, which increases the outflow of aqueous humor through the physiologic drainage pathways.<sup>5</sup> It consists of performing a 360° cannulation of Schlemm's canal using a 10–0 Prolene thread and leaving a tension suture with viscoelastic to provide inward distension of the canal, providing a better aqueous filtration. The patency of the canal, which can be measured postoperatively by ultrasound biomicroscopy, seems to correlate with the extent of IOP reduction.<sup>6</sup> Moreover, the aqueous humor outflow through the uveoscleral pathway may be enhanced through an increase in the conjunctival microcysts seen on confocal laser scanning microscopy.<sup>7</sup> Several studies have demonstrated the efficacy and safety of canaloplasty and have demonstrated comparable results.<sup>6,8,9</sup>

In patients who do not develop a satisfactory response after canaloplasty, further surgical intervention can be performed. While some surgeons have opted for a traditional incisional filtering surgery (trabeculectomy or tube), some have suggested a MIST, a minimally invasive ab interno procedure complementary to the canaloplasty, consisting of pulling the 10-0 Prolene suture left in the Schlemm's canal after canaloplasty, and creating a 360° trabeculotomy. MIST provided satisfactory IOP reduction in patients postcanaloplasty in at least two retrospective studies.<sup>10,11</sup>

The aim of the following retrospective study is to report the efficacy of ab interno canaloplasty revision with MIST in patients who have failed canaloplasty in our center, evaluating IOP reduction, NGM needed postoperatively, and the need for secondary surgical or laser intervention over a follow-up period of 24 months.

## MATERIALS AND METHODS

### Study Design

A retrospective analysis was performed on eyes with glaucoma, meeting eligibility criteria, on whom an ab interno canaloplasty, followed by an ab interno suture trabeculotomy were performed at l'Hôpital Maisonneuve-Rosemont, Montreal, Canada, between 2013 and 2017. Patients were selected for ab interno suture trabeculotomy if they showed progression of glaucomatous damage on visual fields or repeatedly demonstrating an IOP above

target despite maximal topical therapy, after canaloplasty. Written consent was obtained preoperatively from all patients.

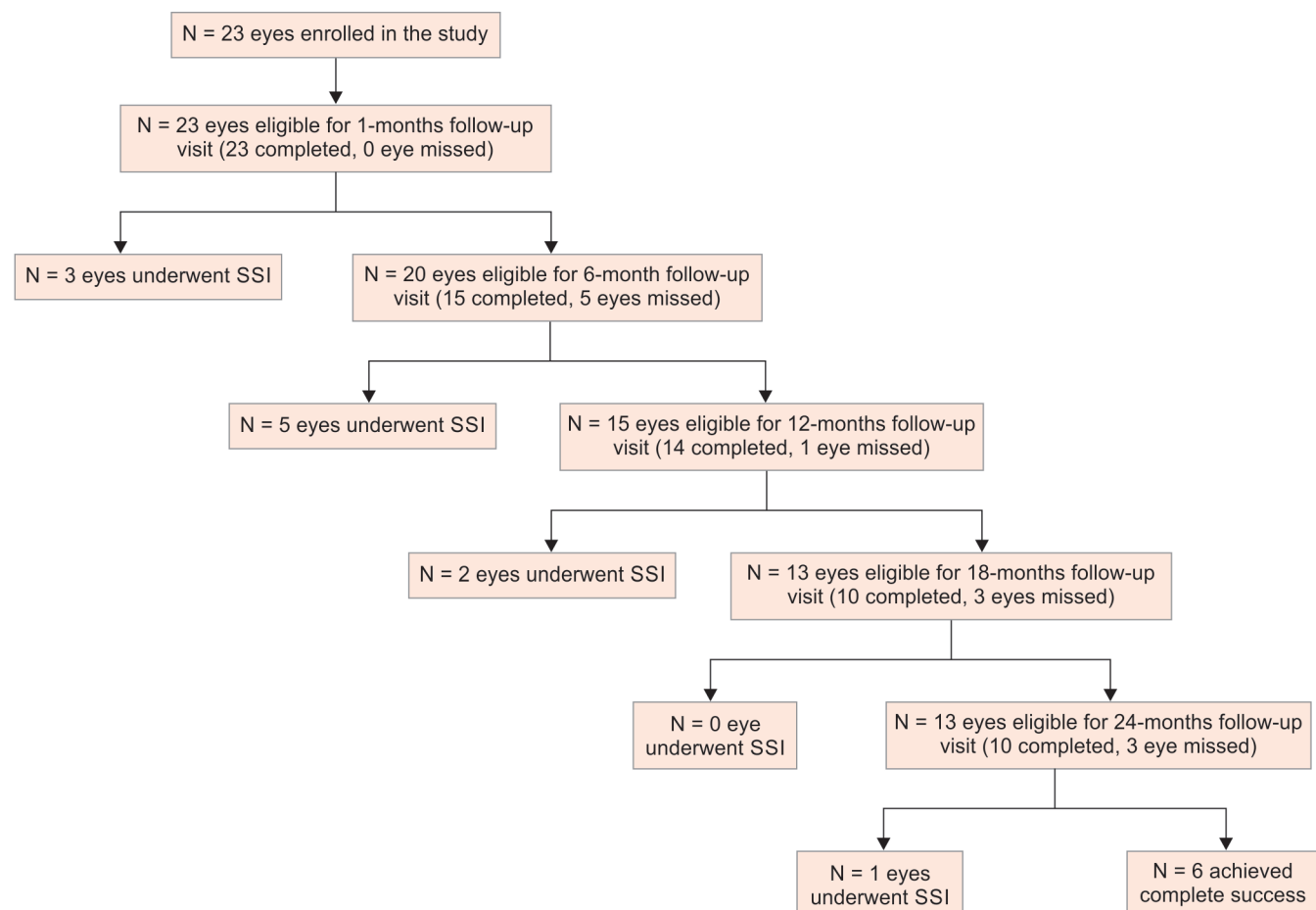
Eligibility criteria were the following: diagnosis of OAG with angle Shaffer grade  $\geq 3$ , a canaloplasty of at least 180° and an ab interno suture trabeculotomy of at least 90°, 0-5 topical ocular hypotensive medications used pre ab interno suture trabeculotomy, with combination drops counted as the number of individual components. Patients were ineligible if they had a form of glaucoma other than OAG, preoperative IOP  $\geq 40$  mm Hg, or if they underwent any pressure-lowering procedures  $\leq 6$  weeks before trabeculotomy.

Patients were followed up over a 2-year period. Medical records were reviewed for demographic information, past medical history, preoperative, and postoperative ophthalmic exams. Results at 1, 6, 12, 18, and 24 months postoperatively were reported at intervals recommended by the World Glaucoma Association in guidelines on the design and reporting of glaucoma surgical trials (2009). All eyes that required one or more additional glaucoma surgery after trabeculotomy were excluded from the analysis at every time point (Fig. 1).

The study followed the tenets of the Declaration of Helsinki and was approved by the Local Ethics Committee.

### Preoperative Assessment

All patients underwent a complete ophthalmic exam, including measurement of BCVA, Goldmann applanation tonometry,



**Fig. 1:** Patient disposition throughout the study. Patients eligible for every follow-up visit were divided into eyes completing the visit and eyes missing the visit. The missing data due to a procedure not being done or a missed visit were treated as missing. Eyes undergoing a secondary surgical or laser procedure (SI) were excluded from the study at every analysis point

gonioscopy, biomicroscopy, and dilated fundus examination. The findings of this exam were considered BL in this study.

### Surgical Technique

After the application of pilocarpine 2% drops, the ocular surface was anesthetized with tetracaine, and the eye was draped in the usual sterile fashion. A 23 G paracentesis was performed at the 6 o'clock position. Healon GV® (Johnson & Johnson Medical Corporation, New Brunswick, USA) was used to fill the anterior chamber to maintain its depth and to help control potential hemorrhage. The 23 G forceps were used to grab the 10-0 nonabsorbable polypropylene suture (Prolene, Ethicon, Johnson & Johnson Medical Corporation, New Brunswick, USA) already present inside Schlemm's canal at the 12 o'clock position. A Swan-Jacob gonio lens was used to assist in identifying its location. The suture was then removed gently with the forceps and pulled toward the anterior chamber, establishing a 360° trabeculotomy. The suture was then removed from the anterior chamber and Healon GV® was washed out along with possible blood (Fig. 2). Postoperatively, the patients were advised to refrain from any kind of physical effort and to keep the head elevated for 2 weeks.

The postoperative medication regimen included 1 week of topical moxifloxacin, one drop four times daily, and 2 weeks of pilocarpine 1%, one drop three times daily to prevent synechiae formation.

### Outcome Measures

Data analysis was performed to evaluate BCVA, IOP, and the NGM over a 2-year period at 1, 6, 12, 18, and 24 months.

The primary outcome of this study was the success of the trabeculotomy, defined as an IOP  $\leq 18$  mm Hg or  $\geq 20\%$  reduction in IOP compared to pretrabeculotomy measurements without any secondary surgical or laser intervention, and with the same or fewer NGM. The success of the procedure was defined by both an IOP target and an IOP percent reduction target to include patients who need better IOP control on fewer medications and patients with IOP above the target who need IOP reduction. An IOP of 18 mm Hg or below is deemed acceptable for preventing glaucoma progression for patients with mild disease,<sup>12</sup> and a 20% reduction after an IOP-lowering intervention is the recommended primary effectiveness endpoint by the United States Food and Drug Administration guidance for industry: premarket studies of implantable MIGS devices. These endpoints were also used in other studies investigating the efficacy of ab interno trabeculotomy postcanaloplasty.<sup>13</sup>



**Fig. 2:** Intraoperative gonio-photograph of the open angle after removal of the 10-0 Prolene suture

The secondary outcomes were IOP, median percent change in IOP from preoperative BL, BCVA, NGM, and the need for an SI at 1, 6, 12, 18, and 24 months post trabeculotomy.

### Statistical Analysis

Statistical analysis was performed with the Statistical Package for the Social Sciences (SPSS) software (IBM SPSS Statistics, Version 27). Demographics and BL characteristics were analyzed with descriptive statistics [mean, maximum, minimum, and standard deviation (SD)]. Values were reported as a mean  $\pm$  SD, with a 95% confidence interval (CI). The proportions for the primary binary outcome, corresponding standard errors, and confidence bounds at each time (1, 6, 12, 18, and 24 months) were calculated. The mean BCVA, IOP, NGM, and number of SI needed were calculated at each point in time and compared with BL using the student's paired *t*-test with *p*-values  $< 0.05$  considered to reflect a statistically significant difference. For eyes that required an SI, data after the SI was excluded from the analysis set; these eyes were treatment failures for binary endpoints. The missing data due to a procedure not being done or a missed visit were treated as missing. No imputation was carried out.

## RESULTS

### Recruitment and Retention

This retrospective case series enrolled a total of 23 eyes of 21 patients with OAG treated with micro-invasive 360° suture trabeculotomy after canaloplasty from 2013 to 2017 at l'Hôpital Maisonneuve-Rosemont, Montréal, Canada, and completed a 24-month follow-up. The mean age at trabeculotomy was  $58.4 \pm 10.2$  years, with 52.2% males and 47.8% females, and most eyes belonged to Caucasian patients (95.7%). All eyes had OAG, with 95.7% having primary OAG (POAG) and 4.3% of eyes having pigment dispersion syndrome (PDS).

### BL Patient Characteristics

Baseline (BL) BCVA was  $0.3 \pm 0.4$  logarithm of the minimum angle of resolution, BL NGM was  $3.6 \pm 0.8$  (two to five medications), BL IOP  $23.1 \pm 6.8$  mm Hg (13–39 mm Hg). The mean cup-to-disc ratio (C/D) was  $0.84 \pm 0.08$  (0.70–0.95) (Table 1).

**Table 1:** Demographic and BL characteristics

Variable	All (N = 23)
Gender	
Female (n, %)	11 (47.80)
Male (n, %)	12 (52.20)
Age at trabeculotomy (years, mean $\pm$ SD)	$58.4 \pm 10.2$
Diagnosis	
POAG (% , n)	95.70 (22)
PDS (% , n)	4.30 (1)
Race	
Caucasian (% , n)	95.70 (22)
African American (% , n)	4.30 (1)
BCVA (Log MAR, mean $\pm$ SD)	$0.3 \pm 0.4$
IOP (mm Hg, mean $\pm$ SD)	$23.1 \pm 6.8$
NGM (mean $\pm$ SD)	$3.6 \pm 0.8$
C/D (mean $\pm$ SD)	$0.84 \pm 0.08$

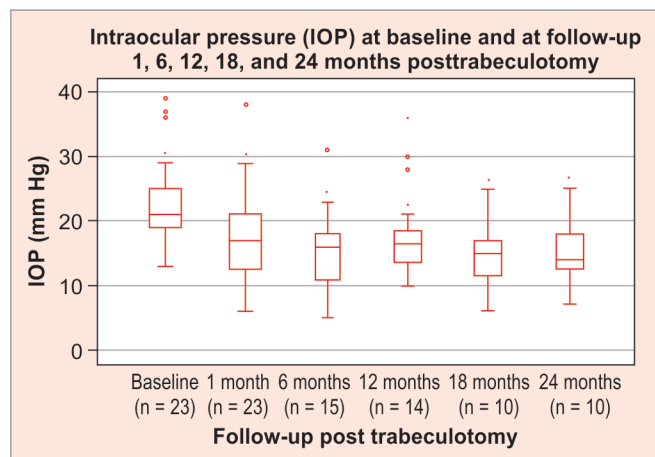
BCVA, best corrected visual acuity; C/D, cup-to-disc ratio; IOP, intraocular pressure; NGM, number of glaucoma medications; PDS, pigment dispersion syndrome; POAG, primary open-angle glaucoma

### Treatment Effectiveness

Primary effectiveness was defined as the proportion of all eyes achieving an IOP  $\leq 18$  mm Hg or  $\geq 20\%$  reduction in IOP from the preoperative BL while on the same or fewer ocular hypotensive medications as compared to BL and without the need for an SI for IOP control at 12 months postsurgery. Only eight out of 23 eyes ( $36.4 \pm 10.5\%$ , 95% CI: 18.2–59.1%) achieved success.

The mean IOP, BCVA, and NGM at each visit were compared to the BL. A significantly lower mean IOP was recorded at all visits ( $p < 0.05$ ), reaching  $17.5 \pm 5.8$  mm Hg at 12 months and  $14.3 \pm 4.0$  mm Hg at 24 months, compared to  $23.1 \pm 6.8$  mm Hg preoperatively (Fig. 3). The percent IOP change was  $16.4 \pm 49.9\%$  1 month postoperatively and increased to  $27.3 \pm 36.8\%$  at 24 months postoperatively.

The NGM prior to surgery was  $3.6 \pm 0.8$ , decreased to  $3.2 \pm 1.5$  at 12 months, and  $3.3 \pm 1.6$  at 24 months postoperatively, but the decrease was not statistically significant, except at 1 month postoperatively, where the number of medications dropped to  $3.2 \pm 1.1$ . At 12 months, the number of eyes needing the same or fewer NGM after MIST was nine ( $40.9 \pm 10.3\%$ , 95% CI: 22.7–59.1%),



**Fig. 3:** Whiskers and box plot showing the IOP at BL and at follow-up 1, 6, 12, 18, and 24 months post trabeculotomy. The box plot represents the values falling in the interquartile range, between the 25th and 75th percentile, while the low and high whiskers represent the values falling below the 25th percentile and above the 75th percentile, respectively. The outliers are represented by the circles. The line dividing the box plot represents the median value. The asterisks represent a statistically significant difference between the mean IOP at the follow-up visit compared to BL ( $p \leq 0.05$ )

and it decreased to five eyes ( $21.7 \pm 8.7\%$ , 95% CI: 4.3–39.1%) at 24 months postoperatively. Only one eye remained medication-free 24 months post-suture trabeculotomy.

A total of 11 eyes ( $47.8 \pm 10.6\%$ , 95% CI: 26.1–69.6%) needed a secondary surgical or laser intervention at 24 months post-MIST throughout the follow-up period, detailed in Table 2. Out of the 11 eyes undergoing SI, five eyes (45.5%) required the procedure 6 months after MIST. At 24 months post-MIST, only one eye required an SI. BCVA was stable at all visits, with nonsignificant fluctuations.

Consequently, 11 eyes ( $36.4 \pm 10.5\%$ , 95% CI: 18.2–59.1%) of the patients achieved complete success at 12 months; the proportion was lower at 24 months, where only six eyes ( $27.3 \pm 9.6\%$ , 95% CI: 9.1–50.0%) of the patients maintained complete success (Table 3).

### DISCUSSION

Management of glaucoma presents multiple challenges at different stages of care: early diagnosis, selection of an adequate IOP target, choice of treatment modality, patients' compliance to medical therapy, and regular follow-up. Compliance plays a substantial role in either the success or failure of treatment and is not easy to achieve because of the negative impact that the diagnosis and treatment of glaucoma have on the patient's quality of life.<sup>11,12</sup>

The burden of medical therapy is alleviated by surgical procedures, where the treating physician aims at a better and more stable IOP reduction, with as fewest pressure-controlling medications as possible. MIGS can be performed early during the disease in selected patients, allowing better control of IOP with fewer medications and, consequently, better prevention of disease progression and improved quality of life, with a better safety profile compared to traditional incisional glaucoma surgery.<sup>4</sup>

Canaloplasty has shown comparable efficacy and a good safety profile in multiple studies.<sup>6,8,9</sup> A follow-up study by Brusini showed that a mean IOP of  $17.0 \pm 4.2$  mm Hg (42.2% IOP reduction) was achieved 1-week postcanaloplasty, with 86.2% of eyes maintaining IOP  $\leq 21$  mm Hg on an average of  $1.3 \pm 1.5$  medications 4 years after surgery.<sup>9</sup>

In patients who do not develop a satisfactory response after canaloplasty, a MIST is a minimally invasive ab interno procedure that was suggested as complementary to the canaloplasty to optimize the surgical outcome, or in case canaloplasty does not provide satisfactory IOP reduction, which was proven to work in at least two retrospective studies. Among "nonresponders" to canaloplasty, MIST led to an IOP decrease to around 13.0 mm Hg

**Table 2:** Secondary surgical or laser interventions that patients underwent after every follow-up visit

Visit	SI						Total (n, %)
	Surgical procedure				Laser procedure		
	Needling	MIGS	NPGS	TR	SLT	CPC	
1 month	3	0	0	0	0	0	3 (27.3)
6 months	1	0	2	1	1	0	5 (45.5)
12 months	0	1	0	0	0	1	2 (18.2)
18 months	0	0	0	0	0	0	0 (0.0)
24 months	0	0	0	0	0	1	1 (9.1)
Total (n, %)	4 (36.4)	1 (9.1)	2 (18.2)	1 (9.1)	1 (9.1)	2 (18.2)	11 (100)

CPC, cyclophotocoagulation; MIGS, minimally invasive glaucoma surgery; NPGS, Nonpenetrating glaucoma surgery; SLT, selective laser trabeculoplasty; TR, tube revision



**Table 3:** Complete success of minimally invasive suture trabeculotomy. Success was defined as the proportion of all eyes achieving an IOP  $\leq$  18 mm Hg or  $\geq$ 20% reduction in IOP compared to BL while on the same or fewer ocular hypotensive medications, without the need for subsequent glaucoma surgery, at 1, 6, 12, 18, and 24 months postsurgery

Visit	n	%	SD	Complete success of MIST surgery	
				95% CI	
				Lower	Upper
1 month	13	59.1	10.8	36.4	77.3
6 months	7	31.8	10	13.6	54.5
12 months	8	36.4	10.5	18.2	59.1
18 months	6	27.3	9.7	9.1	45.5
24 months	6	27.3	9.5	9.1	45

with a percent reduction of around 40% 12 months post-MIST, along with a decrease in the number of pressure-lowering medication to 1.5, and no sight-threatening adverse events.<sup>10,11,14</sup>

However, our study showed that MIST failed to improve the IOP target in canaloplasty nonresponders, as most patients ended up requiring additional glaucoma procedures. A possible explanation for our findings is that in MIST, a 10–0 polypropylene suture is used, which may be too thin to leave behind an adequately opened TM after trabeculotomy, especially in an eye where canaloplasty has already failed. The use of a thicker suture, such as the 5–0 polypropylene suture used in a gonioscopy-assisted transluminal trabeculotomy (GATT), could lead to a more successful trabeculotomy. GATT procedure is a safe and successful option for the treatment of moderate to advanced OAG, with up to 44% decrease in IOP to  $\geq$ 18 mm Hg in  $>90\%$  of the patients and a smaller number of pressure-lowering therapy, maintained for up to 18 months.<sup>15–18</sup> Sight-threatening complications occur scarcely, with hyphema as the most common complication reported in around 36% of cases.<sup>19</sup> Therefore, we suggest that using a thicker suture, such as in GATT, could lead to a greater efficacy of MIST, a hypothesis that should be tested by comparing the MIST success rate using a 10–0 polypropylene suture vs a 5–0 polypropylene suture. Failure of this procedure could also stem from the choice of patients, as patients with more advanced glaucoma may not be good candidates for such a procedure. In future studies, the effectiveness of the procedure should be studied in patients with different glaucoma stages.

Limitations of this study include small sample size and lack of diversity, as almost all patients were Caucasian. Previous studies showed that canaloplasty and trabeculotomy had a higher risk of failure in African Americans and Hispanics; hence the results of this study are not generalizable. Additionally, some patients were lost to follow-up or had missed appointments. Given the retrospective design of this study, confounding and selection biases exist.

## CONCLUSION

In conclusion, ab interno trabeculotomy with 10–0 Prolene in patients with failed canaloplasty was not shown to be effective in providing a satisfactory control of IOP in patients with OAG.

## CLINICAL SIGNIFICANCE

Additional work is needed to identify the group of patients who could benefit better from this procedure or to optimize the procedure in terms of technique or suture size.

## ORCID

Roland Seif  <https://orcid.org/0000-0001-6046-5916>

Nahia Dib El Jalbout  <https://orcid.org/0000-0003-1344-0075>

Ama Sadaka  <https://orcid.org/0000-0002-1438-1831>

Andrei-Alexandru Szigiato  <https://orcid.org/0000-0003-0862-9068>

Paul Harasymowycz  <https://orcid.org/0000-0003-2524-7811>

## REFERENCES

- GBD 2019 Blindness and Vision Impairment Collaborators, Vision Loss Expert Group of the Global Burden of Disease Study. Causes of blindness and vision impairment in 2020 and trends over 30 years, and prevalence of avoidable blindness in relation to VISION 2020: the right to sight: an analysis for the global burden of disease study. *Lancet Glob Health* 2021;9(2):e144–e160. DOI: 10.1016/S2214-109X(20)30489-7
- Weinreb RN, Aung T, Medeiros FA. The pathophysiology and treatment of glaucoma: a review. *JAMA* 2014;311(18):1901–1911. DOI: 10.1001/jama.2014.3192
- Conlon R, Saheb H, Ahmed II. Glaucoma treatment trends: a review. *Can J Ophthalmol* 2017;52(1):114–124. DOI: 10.1016/j.cjco.2016.07.013
- Fellman RL, Mattox C, Singh K, et al. American glaucoma society position paper: microinvasive glaucoma surgery. *Ophthalmol Glaucoma* 2020;3(1):1–6. DOI: 10.1016/j.ogla.2019.12.003
- Cagini C, Peruzzi C, Fiore T, et al. Canaloplasty: current value in the management of glaucoma. *J Ophthalmol* 2016;2016:7080475. DOI: 10.1155/2016/7080475
- Lewis RA, von Wolff K, Tetz M, et al. Canaloplasty: circumferential viscodilation and tensioning of schlemm canal using a flexible microcatheter for the treatment of open-angle glaucoma in adults: two-year interim clinical study results. *J Cataract Refract Surg* 2009;35(5):814–824. DOI: 10.1016/j.jcrs.2009.01.010
- Mastropasqua L, Agnifili L, Salvatella ML, et al. In vivo analysis of conjunctiva in canaloplasty for glaucoma. *Br J Ophthalmol* 2012;96(5):634–639. DOI: 10.1136/bjophthalmol-2011-301058
- Lewis RA, von Wolff K, Tetz M, et al. Canaloplasty: three-year results of circumferential viscodilation and tensioning of schlemm canal using a microcatheter to treat open-angle glaucoma. *J Cataract Refract Surg* 2011;37(4):682–690. DOI: 10.1016/j.jcrs.2010.10.055
- Brusini P. Canaloplasty in open-angle glaucoma surgery: a four-year follow-up. *Sci World J* 2014;2014:469609. DOI: 10.1155/2014/469609
- Voykov B, Szurman P, Dimopoulos S, et al. Micro-invasive suture trabeculotomy after canaloplasty: preliminary results. *Clin Exp Ophthalmol* 2015;43(5):409–414. DOI: 10.1111/ceo.12482
- Seuthe AM, Januschowski K, Szurman P. Micro-invasive 360-degree suture trabeculotomy after successful canaloplasty – one year results. *Graefes Arch Clin Exp Ophthalmol* 2016;254(1):155–159. DOI: 10.1007/s00417-015-3192-y
- The AGIS Investigators. The Advanced Glaucoma Intervention Study (AGIS): 7. The relationship between control of intraocular pressure

- and visual field deterioration. *Am J Ophthalmol* 2000;130(4):429–440. DOI: 10.1016/s0002-9394(00)00538-9
13. Vold SD, Williamson BK, Hirsch L, et al. Canaloplasty and trabeculotomy with the OMNI system in pseudophakic patients with open-angle glaucoma: the ROMEO study. *Ophthalmol Glaucoma* 2021;4(2): 173–181. DOI: 10.1016/j.ogla.2020.10.001
14. Baumgarten S, Kürten D, Lohmann T, et al. Outcomes of 360° suture trabeculotomy after unsuccessful canaloplasty. *Graefes Arch Clin Exp Ophthalmol* 2020;258(2):387–393. DOI: 10.1007/s00417-019-04545-2
15. Rahmatnejad K, Pruzan NL, Amanullah S, et al. Surgical outcomes of gonioscopy-assisted transluminal trabeculotomy (GATT) in patients with open-angle glaucoma. *J Glaucoma* 2017;26(12):1137–1143. DOI: 10.1097/ijg.0000000000000802
16. Aktas Z, Ucgul AY, Bektas C, et al. Surgical outcomes of Prolene gonioscopy-assisted transluminal trabeculotomy in patients with moderate to advanced open-angle glaucoma. *J Glaucoma* 2019;28(10):884–888. DOI: 10.1097/IJG.0000000000001331
17. Fontana L, De Maria M, Iannetta D, et al. Gonioscopy-assisted transluminal trabeculotomy for chronic angle-closure glaucoma: preliminary results. *Graefes Arch Clin Exp Ophthalmol* 2022;260(2):545–551. DOI: 10.1007/s00417-021-05400-z
18. Zhao Y, Li A, Cao JL, et al. Two-year outcomes after gonioscopy-assisted transluminal trabeculotomy (GATT) for open-angle glaucoma. *Invest Ophthalmol Vis Sci* 2020;61(7):954.
19. Guo CY, Qi XH, Qi JM. Systematic review and meta-analysis of treating open angle glaucoma with gonioscopy-assisted transluminal trabeculotomy. *Int J Ophthalmol* 2020;13(2):317–324. DOI: 10.18240/ijo.2020.02.17